

A Safe and Physiologic Method for a Less Bloody Surgical Field in Diabetic Foot Surgery: Elevation With the Trapezoid Pillow

Muzaffer Altindas, MD,¹ Can Cinar, MD,² and Ali Kilic, MD³

Bleeding from the site of surgery generally leads to obscurity of the surgical field, which may complicate the execution of the procedure. It also increases the duration of the operation and may necessitate blood transfusion. Although bleeding from large and medium size vessels can be controlled by using electrocoagulation and ligation of the vessel, capillary oozing and bleeding from the small size vessels can persist. Any attempt to stop this type of bleeding with electrocoagulation may damage tissues and cause wound healing problems.

The use of esmarch bandages or tourniquets in upper and lower extremity surgery allows surgeons to work in a bloodless surgical field. For years this modality has been used to provide comfortable and successful operation in extremity surgery. Conversely, there are some reports regarding serious complications due to the tourniquet or esmarch bandage use such as nerve palsy (1), edema in extremity (2, 3), vascular damage (4), degloving injuries to fragile skin in elderly patients (5), and massive pulmonary embolism (5–8). Many of these reported complications were seen in patients having no co-morbidities.

Operation on diabetic foot requires delicate surgical techniques to minimize surgical trauma that is crucial for successful outcomes. Because the use of esmarch bandages or tourniquets may cause severe complications even in healthy people, we developed an alternative method to minimize bleeding in surgery of the diabetic foot. A trapezoid pillow was designed not only to decrease bleeding but also to improve access and exposure in diabetic foot surgery, and is presented herein.

The Trapezoid Pillow

The trapezoid pillow is primarily made of sponge and covered with leather (Fig 1). The height of the pillow is 35 cm, bottom length is 50 cm, upper surface length is 35 cm, and the width is 35 cm. The aim of trapezoid shape design is to support the thigh. The mechanism of action is simply based on the elevation of the extremity, which eventually reduces the blood flow and increases the venous return.

After the completion of anesthesia, the legs of the patient are slightly flexed to about 30° at the hip joints. The involved lower extremity is laid on the trapezoid pillow that has been covered with a sterile table cover. The draping procedure is then completed. The slanted trapezoid end is placed under the thigh, which flexes the knee approximately 45°, and the calf and foot are laid on top of the pillow horizontally. We refer to this position as “standard position” (Fig 2). We start all of our operations in this position and usually also conclude with the leg in this position. Once the operation commences, if there is too much bleeding, we change the position of the whole table toward the trendelenburg position approximately 30°, to further elevate the extremity. Conversely, if we do not see any bleeding at the surgical field when the patient is at standard position, we change the position of the whole table toward the reverse trendelenburg position approximately 30° to lower the extremity. This maneuver allows for intraoperative assessment of blood flow to the foot, which is an important predictor of wound healing.

Discussion

There are many negative factors associated with diabetes mellitus that may compromise healing, such as angiopathy, neuropathy, chronic renal failure with uremia, ischemic heart disease with previous bypass surgery, and a decreased ability to resist infection. Therefore, it can be hypothesized that tourniquet use and a period of local ischemia may cause more tissue damage than in nondiabetic patients. Vascular disease, previous bypass surgery, and deep vein thrombosis, which are commonly associated with diabetes mellitus, are

Address correspondence to: Ali Kilic, MD, Merkezefendi mah, Tercuman sitesi, A4 blok D:14, 34015, Istanbul, Turkey. E-mail: dralikilic@hotmail.com

¹Professor, Department of Plastic, Reconstructive and Aesthetic Surgery, Istanbul University Cerrahpasa Medical School, Istanbul, Turkey.

²Clinical fellow, Department of Plastic, Reconstructive and Aesthetic Surgery, Istanbul University Cerrahpasa Medical School, Istanbul, Turkey.

³Resident in Plastic Surgery, Department of Plastic, Reconstructive and Aesthetic Surgery, Istanbul University Cerrahpasa Medical School, Istanbul, Turkey.

Copyright © 2006 by the American College of Foot and Ankle Surgeons
1067-2516/06/4502-0013\$32.00/0

doi:10.1053/j.jfas.2005.12.012




FIGURE 1 The trapezoid pillow. The asterisk indicates the groove on the top of the pillow for stabilization of the calf. It also provides more comfort for the patient.

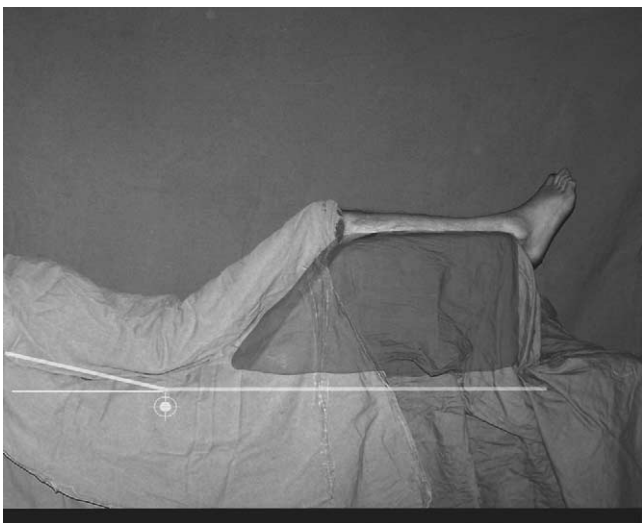


FIGURE 2 The “standard position.”

well-known contraindications to tourniquet use (9). In addition, it may be difficult to determine the viability of tissue when a tourniquet is used (10). On the other hand it is not uncommon for diabetic patients to have bleeding tendency because of the platelet dysfunction from renal disease (11) or aspirin and other anticoagulants use owing to the ischemic heart disease.

In the past we used an esmarch bandage or pneumatic tourniquet to decrease bleeding during diabetic foot surgery. Not uncommonly the pressure required to occlude major vessels approached 500 mm Hg, most likely due to calcification of the vessels. We also observed that major arteries became fragile and the tunica intima layer was seriously damaged in several cases by atherosclerosis. We believe

that surgical procedures such as debridement, flap preparation, graft application, and primary suture should be performed under the guidance of bleeding.

At first we performed diabetic foot surgery by hanging the foot from the ceiling with a rope to provide elevation. Although bleeding from the surgical area decreased enough by this method, there was no capacity to avoid ischemia. We also realized that both popliteal vessels and tibial nerve were being stretched excessively due to hyperextension of the knee. The foot was also swinging side-to-side, which also made surgery difficult. We tried to elevate the lower extremity by placing a bolster of towels under the leg, but it provided inconsistent positioning of the extremity. Later on, we charged an assistant to hold the lower extremity during the surgery. However, it was not a comfortable position for both the surgeon and the patient. Finally, we designed the trapezoid pillow for effective elevation of the lower extremity.

Total cessation of blood supply to tissues with tourniquet or esmarch bandage, even for a short period of time, is not physiologic. Elevation with trapezoid pillow provides a safe and physiologic means of decreasing the amount of bleeding at the surgical area. All known complications of tourniquet use can be avoided with the use of this simple and easily accessible method for the elevation of the lower extremity in diabetic foot surgery.

References

1. Kornbluth ID, Freedman MK, Sher L, Frederick RW. Femoral, saphenous nerve palsy after tourniquet use: a case report. *Arch Phys Med Rehabil* 84:909–911, 2003.
2. Ward CM. Oedema of the hand after fasciectomy with or without tourniquet. *Hand* 8:179–185, 1976.
3. Silver R, de la Garza J, Rang M, Koreska J. Limb swelling after release of a tourniquet. *Clin Orthop* 206:86–89, 1986.
4. Hagan PF, Kaufman EE. Vascular complication of knee arthroplasty under tourniquet. A case report *Clin Orthop* 257:159–161, 1990.
5. Marshall PD, Patil M, Fairclough JA. Should esmarch bandages be used for exanguination in knee arthroscopy and knee replacement surgery? A prospective trial of esmarch exanguination versus simple elevation *J R Coll Surg Edinb* 39:189–190, 1994.
6. Paez Hospital M, Herrero Gento E, Buisan Garrido F. Pulmonary embolism after placement of an esmarch bandage for ankle surgery. *Rev Esp Anestesiol Reanim* 50:192–196, 2003.
7. Darmanis S, Papanikolaou A, Pavlakis D. Fatal intra-operative pulmonary embolism following application of an esmarch bandage. *Injury* 33:761–764, 2002.
8. Boogaerts JG. Lower limb exanguination and embolism. *Acta Anaesthesiol Belg* 50:95–98, 1999.
9. Kalla TP, Younger A, McEwen JA, Inkpen K. Survey of tourniquet use in podiatric surgery. *J Foot Ankle Surg* 42:68–76, 2003.
10. Attinger CE, Bulan EJ. Debridement. The key initial first step in wound healing *Foot Ankle Clin* 6:627–660, 2001.
11. Boccardo P, Remuzzi G, Galbusera M. Platelet dysfunction in renal failure. *Semin Thromb Hemost* 30:579–589, 2004.